

Jonker, Leon, Fallahi, Farshid, Saraswathy, Jayadeep J., Edge, John and Dawson, Matt (2019) OPTY-LINE remote-controlled adjustable intramedullary device implantation in open-wedge high tibial osteotomy: a prospective proof-of-concept pilot and comparison with Tomofix fixed-plate device method. *Journal of Orthopaedic Surgery*, 27 (3).

Downloaded from: <http://insight.cumbria.ac.uk/id/eprint/5039/>

Usage of any items from the University of Cumbria's institutional repository 'Insight' must conform to the following fair usage guidelines.

Any item and its associated metadata held in the University of Cumbria's institutional repository Insight (unless stated otherwise on the metadata record) may be copied, displayed or performed, and stored in line with the JISC fair dealing guidelines (available [here](#)) for educational and not-for-profit activities

provided that

- the authors, title and full bibliographic details of the item are cited clearly when any part of the work is referred to verbally or in the written form
 - a hyperlink/URL to the original Insight record of that item is included in any citations of the work
- the content is not changed in any way
- all files required for usage of the item are kept together with the main item file.

You may not

- sell any part of an item
- refer to any part of an item without citation
- amend any item or contextualise it in a way that will impugn the creator's reputation
- remove or alter the copyright statement on an item.

The full policy can be found [here](#).

Alternatively contact the University of Cumbria Repository Editor by emailing insight@cumbria.ac.uk.

1 **Title:** OPTY-LINE remote-controlled adjustable intramedullary device implantation in opening
2 wedge high tibial osteotomy; prospective proof-of-concept pilot and comparison with Tomofix
3 fixed plate device method.

4 **Abstract** [250 words max; currently 239 words]

5 *Purpose* The objective was to evaluate the degree of bone regeneration achieved after opening
6 wedge high tibial osteotomy (HTO), comparing case series treated with OPTY-LINE and Tomofix
7 fixed-plate device respectively. Furthermore, surgical and patient-reported outcomes were
8 assessed for each modality.

9 *Patients & Methods* Males with symptomatic medial compartmental osteoarthritis and no
10 serious (co-morbid) knee pathology were followed-up, five Tomofix and six OPTY-LINE patients.
11 Patients underwent CT assessment and completed KOOS and osteotomy surgery patient
12 satisfaction questionnaires, 3 and 6 months post-surgery. A radiologist impression score and a
13 quantitative digital density analysis were performed by two independent radiologists.

14 *Results* At six months post-surgery, for Tomofix the median healing impression score was
15 'progressive healing' – equivalent to a mean bone healing quotient of 1.30 [standard deviation
16 1.74]. For OPTY-LINE the median score was 'union virtually complete', $p = 0.041$, whereas the
17 bone healing quotient was 1.78 [SD 1.58], $p = 0.089$. The post-operative absolute surgical
18 accuracy was a mean 4.1 [2.3] for OPTY-line versus 12 [7.5] for Tomofix ($p = 0.052$). At baseline,
19 however, Tomofix patients had more knee symptoms, as determined by KOOS symptom sub-
20 score, when compared to the OPTY-LINE cohort ($p = 0.009$).

21 *Conclusion* Patients implanted with the OPTY-LINE device for HTO exhibit significantly
22 accelerated post-surgical bone regeneration and higher surgical accuracy compared to Tomofix

23 patients. Large-scale controlled studies with longer follow-up are indicated to further evaluate
24 the clinical and patient-related outcome performance of OPTY-LINE to confirm these initial
25 findings.

26

27 **Keywords:** bone regeneration, bone healing, computerized tomography, high tibial osteotomy,
28 intramedullary device, KOOS score.

29

30

31 **Introduction**

32

33 Angle stable plates are the current implants of choice in opening-wedge high tibial osteotomy
34 (HTO) offering increased stability and earlier post-operative weight-bearing than their
35 predecessors.^{1,2} Some authors have described full-weight bearing as early as two weeks post-
36 surgery without negative impact.³ Tomofix patients tend to resume normal activities of living
37 soon after surgery with work-related physical activities introduced at 3 to 4 months and sports
38 after approximately 6-12 months.^{6,7} One reservation for allowing patients to fully weight bear
39 early on is the perceived risk of loss of correction of the angle, although in practice this effect
40 appears to be a rare occurrence.^{1,8,9} Histologically, there is variability in the degree of healing
41 and indeed maturation of bone regeneration achieved in the open wedge. With current fixed
42 plate devices, even 18 months post-procedure, a minor subset of patients will not have
43 significant signs of regeneration in the gap.⁴

44 Gradual HTO wedge-opening and stabilization can be achieved with the recently CE-marked
45 OPTY-LINE system (NuVasive Specialized Orthopedics, San Diego, USA). The OPTY-LINE device is
46 an extendable nail which is inserted into the proximal tibial intramedullary canal after the
47 osteotomy is created in the conventional manner Figure 1A shows a schematic drawing of the
48 full length OPTY-LINE device, including where it is fixed to the tibia. Following surgery the nail is
49 slowly extended over a period of time until the distraction gap and thereby the bone correction
50 angle is satisfactory, as measured by X-ray imaging. Figure 1B demonstrates schematically how
51 the proximal mediolateral (ML) screw changes its angle in relation to the longitudinal axis of the
52 nail as the distraction produces opening of the wedge via the anteroposterior (AP)screw. The
53 null hypothesis is that there would be no difference in outcome for rate of bone healing and
54 surgical accuracy in cases using the new OPTY-LINE design in comparison with cases using the
55 established gold standard Tomofix plate. Timely healing of the osteotomy gap is of clinical
56 importance since it will in the majority of cases allow the patient to resume activities such as
57 sports even if the supporting device is removed.^{6,10} Surgical accuracy is extremely important for
58 successful outcome in high tibial osteotomy.¹¹ Inaccuracy leads to poorer outcomes with higher
59 revision rates or conversion to arthroplasty. The main objective of this comparative study is
60 therefore to assess and quantify the degree of bone regeneration on CT scan and thereby
61 compare the bone healing process between the Tomofix plate and OPTY-LINE system.
62 Furthermore, apart from introducing the surgical methodology for the new OPTY-LINE device,
63 we explore the surgical accuracy achieved post-operatively and how patients perceive the device
64 in terms of post-operative satisfaction rates and functionality of their corrected knee joint.

65

66 **Patients & Methods**

67 *Study design and subjects*

68 The study is a prospective, open label, two-armed, single-centre therapeutic study. The study is
69 registered with ClinicalTrials.gov, identifier NCT02717845. Two cohorts of patients were enrolled
70 into the study without randomisation. The participants either underwent HTO with the OPTY-
71 LINE system or the Tomofix plate (DePuy Synthes, West Chester, USA). Patients were identified
72 prospectively from surgical and clinic lists. Only males were enrolled into the study, to make the
73 study more controlled and for two relevant reasons: to minimise fetal risk with increased
74 ionising radiation; and to avoid confounding due to the known difference in bone density
75 between males and females.¹²

76 A total of 12 patients were recruited into the study and it concerned 7 OPTY-LINE patients and 5
77 Tomofix patients. All patients were male and non-smokers, and they all met the eligibility criteria
78 outlined in section 2.2. One of the OPTY-LINE subjects expired during follow-up, prior to the
79 study follow-up visits, due to non-surgery nor medical device related reasons and therefore 6
80 OPTY-LINE patients remained for analysis. Table 1 shows an analysis of distribution of
81 demographics – and baseline degree of osteoarthritis - and comparison between the two
82 cohorts.

83 *Eligibility criteria*

84 Inclusion criteria were: treatment with medial open wedge proximal tibial osteotomy, either
85 with Tomofix device or OPTY-LINE device for symptomatic medial compartmental osteoarthritis;

86 Provision of written informed consent; Males; Mental capacity. Exclusion criteria were: Under
87 age (< 18 years); Patients lacking mental capacity; Females; Current use of nicotine products,
88 including smoking; Patients who cannot understand English and therefore cannot be consented.
89 Furthermore, the following pre-existing clinical exclusion criteria were applied for potentially
90 eligible patients: Varus deformity greater than 10°; Flexion contracture greater than 15°; Knee
91 flexion under 90°; Medial/lateral tibial subluxation over 1 cm; Medial bone loss of over 3 mm if
92 demonstrated on radiographs; Inflammatory arthritis (including use of methotrexate); Arthritis in
93 the lateral compartment; Patella baja; Weight over 115 kg; Severe patella femoral symptoms;
94 Unaddressed ligamentous instability; Fixed flexion contracture; Known or suspected
95 osteoporosis or osteopenia based on medical history and radiographic image; Requirement for
96 other major surgical procedures at the time of the HTO surgery.

97 *Surgical procedures & Rehabilitation*

98 - Tomofix plate.

99 Opening wedge HTO was conducted according to the method outlined in Osteotomies around
100 the Knee Indications-Planning-Surgical Techniques using Plate Fixators and Elson et al.^{13,14}

101

102 - OPTY-LINE nail.

103 The OPTY-LINE device surgical procedure was performed as follows: With the knee bent at 90-
104 110 degrees with a bolster, medial para patellar approach to the tibial entry point was made.

105 The entry point is at the anterior cortex of the tibia slightly medially in line with the tibial

106 medullary canal. The position was verified with image intensification. Guide wire was inserted

107 and confirmed with orthogonal views to be inside the medullary canal. Reaming was performed
108 to 160 mm x 12.5 mm, and a trial nail was then inserted. The proximal end of the nail should sit
109 flush with the tibial plateau. Following nail insertion, the AP screw is drilled. After removal of the
110 trial nail the high tibial osteotomy was performed as per Elson et al.¹³ Subsequently the OPTY-
111 LINE nail was inserted and locked proximally and distally. After wound closure the magnet inside
112 the nail was then identified and marked on the skin aided by the image intensifier. Post-
113 operative correction is based on pre-operative planning and serial radiographs. Daily correction
114 for each patient was typically 0.5 mm, divided into 2 sessions, starting five to seven days after
115 the operation. Weekly follow up – up to six weeks - with long leg alignment radiograph views
116 were performed to optimise the corrections.

117 - All patients

118 Post-operatively, patients returned to full mobility through the following steps: toe touch in first
119 two weeks, partial weight bearing after 2 to 4 weeks, full weight bearing after 4 to 6 weeks (use
120 of single crutch), and full weight bearing without aids from 6 weeks onwards. To minimize the
121 risk of deep vein thrombosis developing, all patients were treated with a calf pump and
122 administered clexane whilst in hospital, and prescribed rivaroxaban for two weeks once
123 discharged home.

124 *Correction planning and post-operative surgical accuracy assessments*

125 The approach to planning the intended knee joint correction did not differ between the two
126 medical devices. Pre-operative planning and post-operative assessments were conducted
127 according to the method described by Elson et al.¹³ For accuracy calculations, the weight-bearing

128 axis transecting the tibia (% Mikulicz point) was used. The absolute figures for surgical accuracy
129 were calculated in relation to post-operatively achieved Milkulicz line minus the pre-operatively
130 planned Mikulicz line. Therefore a value of zero can be considered a perfect correction.^{15,16}

131

132 *Study schedule*

133 Apart from correction visits for OPTY-LINE patients, all study subjects were seen at baseline
134 (within one month prior to surgery), and 3 & 6 months following their HTO procedure for
135 collation of the patient and clinical outcome measures. At baseline, subject demographics were
136 recorded. During each study visit, the following patient-reported outcome measures (PROMs)
137 were collected: Visual analogue pain scale (standard 10 cm line), KOOS knee health
138 questionnaire²⁰ and an osteotomy patient satisfaction questionnaire (see Annex 1). The latter
139 questionnaire is based on three earlier published questionnaires, adopted for this study.^{17,18,19}

140 *CT imaging details*

141 The primary outcome was the radiologist's assessment of healing, as determined from CT-
142 imaging according to a 5-point Likert scale devised by Brosset et al.²⁰ This was performed by two
143 radiologists, FF (rater 1) and JE (rater 2), each of whom have over 10 years' experience as a
144 consultant radiologist. The Radiologist Impression Scoring system, and what each score equates
145 to, is outlined in Table 2.

146 The CT apparatus used in this study was a Siemens Somatom Sensation (64 Slice) scanner. To
147 minimise unnecessary exposure to ionising radiation, the image acquisition will start 3 cm above

148 the proximal osteotomy line and ending 3 cm below the inferior aspect of the gap. A
149 standardised CT protocol with full detector coverage of 64 Slices, a slice thickness of 0.6 mm,
150 peak kilovoltage of 120, product of tube current and exposure time of 140 mAs effective, and a
151 pitch of 0.9 and a rotation time of 1 second, was used. Images were then reconstructed with
152 very sharp kernel of B70s in 2 mm slices with a reconstruction increment of 2mm. In addition to
153 the aforementioned Radiologist Impression Score, other parameters related to bone healing
154 following HTO were recorded. The osteotomy margin is the angle between the superior
155 osteotomy margin and the articular surface of the medial tibia plateau. In addition, the margin
156 surface appearance was also recorded (smooth vs irregular). The osteotomy gap is the maximum
157 gap within the osteotomy location, measured at the cortex on a coronal field of view. Callus
158 characteristics were also defined for each subject; callus appearance can be divided into
159 irritation callus and fixation callus respectively.²¹ The presence of endosteal and periosteal bone
160 healing was also recorded. In addition to a qualitative bone healing scoring, bone healing was
161 also quantified by applying regions of interest (ROIs), measuring approximately 7mm² in size.
162 This quantitative measurement was performed within the osteotomy gap on coronal
163 reconstruction images on the picture archiving and communication system (PACS). The location
164 of the ROI was as follows: for the defect area the ROI was positioned in the centre of the
165 osteotomy gap between the superior and inferior margins a few millimetres beside the medial
166 cortex of the proximal tibia and for inferior/superior areas it was placed circa 10 mm from the
167 respective osteotomy margins. The purpose of measuring the ROI above and below the level of
168 the osteotomy gap was to deliver references of normal bone marrow density of tibia of the same

169 individual. Bone density of the callus formation was assessed independently by the two
170 abovementioned radiologists, with each using the same coronal mid-point slide.

171

172 *Statistical analysis*

173 Study data was entered in Microsoft Excel and analyses were conducted using SPSS v20. The a-
174 priori power calculation was performed using GPower 3.1 freeware. The required sample size to
175 obtain 80% power and 5% significance was 10 subjects total with 5 subjects per treatment
176 group. This was based on a hypothetical difference in radiologist mean healing score at month 6
177 between the two devices measuring 2, standard deviation of 1, with a one-sided Mann-Whitney
178 U-test applied (exact test outcome). For comparison of quantitative assessment of bone
179 formation between Tomofix and OPTY-line cohorts, Mann-Whitney U-test was also applied.
180 Concordance between the two radiologists' scores was assessed with Kendall's coefficient of
181 concordance. Any statistical difference between the baseline demographics of the two cohorts
182 for demographics was assessed with two-sided Mann-Whitney test for ordinal and continuous
183 data, and Fisher's exact test for binary data. KOOS patient reported outcome data and
184 magnitude of error of accuracy was assessed by application of a two-sided Mann-Whitney U test.
185 In line with the power calculation, for bone density analysis, one-sided Mann-Whitney U-test
186 was applied. Loss to follow-up was not taken into account as subjects were to remain under
187 clinical supervision by the Orthopaedic department during the study period.

188

189 **Results**

190 Table 2 displays the data for the Likert scale radiologist's impression score and also for the
191 quantitative analysis using pixel density on images in PACS. The average bone healing status
192 for OPTY-LINE at 6 months is 'union virtually complete' whereas for Tomofix it is
193 'progressive healing'. These results are mirrored to a large extent with digital quantification
194 analysis at 6 months. The characteristics of the regeneration in the lesion align with the
195 radiologist impression score. At six months, 4 out of 6 OPTY-LINE cases show the presence
196 of fixation callus, whereas this type of more developed callus is only seen in 1 out of 5
197 Tomofix cases. In all other cases irritation callus is the predominant feature. Figure 2 shows
198 representative CT imaging for one Tomofix and one OPTY-LINE patient at 3 and 6 months
199 post-operative respectively. CT imaging also revealed 4 out of 6 type I and 1 out of 6 type II
200 hinge fractures in the OPTY-LINE cohort, whereas in the Tomofix cohort 3 out of 5 patients
201 had a type I and 2 out of 5 had a type II hinge fracture.

202 The surgical accuracy achieved for each patient, and comparison analysis between the two
203 cohorts, is summarised in Table 3. The OPTY-LINE device achieved a median improvement of
204 more than 10 points - equating to achieving a minimal perceptible clinical improvement
205 (MPCI) [22] - for each of the KOOS sub-scales, which are pain, symptoms (, activities of daily
206 living (ADL), sport & recreation (S&R) and quality of life (QoL). KOOS score improvements
207 were also observed in the Tomofix cohort, but to a lesser degree, with only S&R and QoL
208 reaching MPCI levels (full data set available in Annex 2). When compared, of note is the
209 difference in terms of the KOOS score at baseline for OPTY-LINE versus Tomofix (p-value,

210 two-sided Mann-Whitney U-test): pain 68 vs 44 (0.052); symptoms 58 vs 41 (0.009); ADL 71
211 vs 47 (0.052); S&R 22 vs 6 (0.13); and 32 vs 20 (0.33). An initial descriptive patient-reported
212 satisfaction appraisal of each respective treatment shows little to no difference in how they
213 perceive the outcome of the surgery (see Annex 1 for full graph summarising outcomes at 3
214 and 6 months post-surgery). At six months, both OPTY-LINE and Tomofix score a median of
215 'satisfied' for general and pain related patient satisfaction, whereas for daily activities and
216 sports & recreation they both score 'neutral'. The data to some extent mirrors the KOOS
217 data.

218 **Discussion**

219 This is the first report on the use and performance of the OPTY-LINE nail in HTO, and first
220 evidence that the achieved bone regeneration in the osteotomy gap at 6 months post-
221 surgery is significantly better with OPTY-LINE compared to Tomofix. Although the
222 application of the OPTY-LINE device in patients with osteoarthritis is novel, the applied
223 technology is well-established. It has its roots in the PRECICE intramedullary limb
224 lengthening system; a magnetic rod and a motorized external remote controller (ERC) with
225 rotational magnetic field are used to gradually extend the limb.²³ The PRECICE system has
226 been shown to be highly accurate in terms of achieving a desired lengthening.^{24,25}

227 The gradual elongation with OPTY-LINE also allows fine tuning of the MiKulicz correction axis
228 point, whereas with Tomofix the surgeon is dependent purely on pre-operative imaging and
229 calculations to try and achieve an as accurate as possible correction. This is evident from the
230 accuracy results for OPTY-LINE and Tomofix respectively. Where 3 out of 5 Tomofix cases

231 have an absolute accuracy of < 10, in the case of OPTY-LINE all cases are within 10. Even
232 with the small sample size applied in this pilot study, the difference is nearly statistically
233 significant. The range of corrections seen in the Tomofix cohort is not uncommon for HTOs
234 conducted with said device.¹⁶ At 3 months post-surgery both cohorts contain
235 undercorrected and overcorrected cases, whereas at 6 months there are signs – in 5 out of 6
236 cases - that the corrections for OPTY-LINE are not sustained and that there may have been a
237 degree of compression of the osteotomy gap. More cases need to be carried out to
238 ascertain if this is an accidental observation or whether this is a characteristic of the OPTY-
239 LINE device which needs to be taken into account when planning surgery. Loss of correction
240 has previously been shown to be a rarity in HTOs carried out using Tomofix, with only up to
241 2% of cases showing such signs.^{26,27}

242 Regardless of the medical device system applied, for open wedged HTO it is imperative that
243 the open wedge is healed and repopulated by new bone, to restore strength and allow full
244 recovery following HTO. Regeneration will take place naturally, although some surgeons
245 apply aids to promote bone healing, such as allografts or synthetic bone substitutes.
246 Research into filling of the wedge has shown that there is no significant advantage to using
247 the filler – both in terms of stability and bone healing time of the wedge.^{20,28} Therefore, in
248 this present study, for the Tomofix cohort filler was not applied; with OPTY-LINE, since
249 initially only the cut is made and a wedge is created in the weeks post-surgery, filler is not
250 indicated. As mentioned in the introduction, osteotomy patients often wish to return to
251 being physically active, including participation in sports. However, surgeons often find it
252 very difficult to decide when their patient can indeed return to unrestricted sports. This is

253 partially because it is often very difficult to quantify the bone healing process precisely on
254 radiographs. Experiments on osteotomy cases and in other mammals have shown that CT
255 imaging is the best option for appraising healing since radiography overestimates the degree
256 of healing.^{29,30} This study's primary outcomes, the radiologist impression scores and
257 quantitative bone healing quotient scores using CT imaging, were highly comparable at 3
258 and 6 months for each medical device, though lower concordance was found at 6 months,
259 where the standard deviation was much larger for bone healing quotients. This can be
260 explained by the fact that the radiologist impression score is based on an evaluation of the
261 whole lesion, whereas for the digital quantification only one sub-region was captured. Due
262 to the nature of healing, there may be 'hotspots' of healing with callus foci distorting the
263 actual average degree of newly bone formed. Although each patient's natural bone density
264 was taken into account, this artefact could not be avoided because the selected region was
265 in a consistent position within the gap to avoid selection bias. On the other hand, human
266 interpretation of bone regeneration may introduce bias due to the subjective (human
267 assessment) nature of the assessment. There are some signs of this at 3 months with slightly
268 poor concordance, but inter-rater concordance was extremely high for the 6 months
269 samples. Each of the bone regeneration appraisal techniques used, radiologist impression
270 score and bone healing quotient, therefore has a flaw. The combined application of the two
271 approaches is warranted because they corroborate each other. With the assessment
272 techniques in mind, the osteotomy gap in patients fitted with the OPTY-LINE device healed
273 significantly better than those fitted with Tomofix. Whilst OPTY-LINE achieves virtual
274 complete regeneration at 6 months, in the case of Tomofix the healing time stretches

275 beyond six months post-surgery. Previous research has shown that even at one year post-
276 surgery, consolidation of the wedge created with a Tomofix fixed plate is complete in just
277 under 90% of cases.³⁰ Of note is where OPTY-LINE regeneration is observed in the lesion;
278 callus formation is seen in both the lateral and medial compartments (see Figure 2A and 2B).
279 On the other hand, In line with what has previously been reported, the Tomofix osteotomy
280 gap is repopulated from the lateral side (Figure 2C and 2D), beginning at the hinge point
281 where the distance between existing bone is the least.^{30,32} There is a body of evidence
282 supporting the notion that smaller osteotomy gaps heal faster than large gaps.^{33,34} Due to
283 the gradual enlargement of the osteotomy gap, OPTY-LINE lesions can take advantage of
284 this phenomenon. Furthermore, internal fixation with a degree of flexibility encourages
285 bone healing and maturation, resulting in more callus formation.³⁵ This may possibly explain
286 why healing in the OPTY-LINE cases was more advanced than in Tomofix cases. Schröter and
287 colleagues previously showed that unstable hinge fractures and smoking may delay bone
288 healing.³⁵ All the subjects in this study were non-smokers, and therefore this does not pose
289 an issue in terms of potential confounding. As expected using CT in preference to
290 radiography the diagnosis of at least a type 1 fracture was almost universal and three type II
291 fractures were also observed. Since distribution was not skewed towards one cohort in
292 particular, their overall confounding effect (if any) on the relative healing outcomes
293 between the two cohorts is unlikely to be significant but should be borne in mind
294 nonetheless.

295 Despite this being a prospective, clinically and demographically matched comparison of
296 OPTY-LINE and Tomofix, medical device allocation was not random. Furthermore, there was

297 no controlling for KOOS score at baseline, particularly pain before surgery, and in the
298 resulting analysis it transpired that there was a significant difference in said scores between
299 the two cohorts at baseline. This covariate may introduce a degree of bias in terms of
300 patient-related outcome measures post-operatively and possibly even closure of the
301 osteotomy gap if there are biomechanical reasons underpinning the poor KOOS scores. In
302 contrast, OPTY-LINE patients were marginally older on average. Potential bias and the small
303 sample size limit the conclusions that can be drawn on the relative effects each device can
304 have on patients' pain, quality of life and ability to engage in activities of daily living and
305 sports. A future definitive trial will need to address these potential shortcomings, through
306 the introduction of randomisation and stratification for KOOS score. Nonetheless, it appears
307 that OPTY-LINE patients are at a minimum as 'satisfied' as Tomofix patients with the
308 procedure at 6 months post-operation. The trend seen at 3 months for patient satisfaction,
309 with a possibly a poorer performance for OPTY-LINE, may reflect the nature of the new
310 device. OPTY-LINE patients need to undergo the daily elongation procedure for up to six
311 weeks after surgery, whereas Tomofix patients have effectively completed their correction
312 once off the operating table. Since a lot of patients do not return to playing sports after
313 more than six months following HTO ^{6,7,10}, the potential impact of OPTY-LINE on return to
314 physical activity was not assessed in detail in this proof of concept study due to the limited
315 follow-up period. Nonetheless, both OPTY-LINE and Tomofix patients achieved a MPCl at six
316 months in terms of KOOS sports sub-score. The 'neutral' score in terms of patient
317 satisfaction for both devices indicates that it is possibly too early to gauge opinion on this
318 specific topic at six months post-surgery.

319

320 **Conclusions**

321 The OPTY-LINE medical device is a new modality for high tibial open-wedge osteotomy in
322 which post-operative distraction of the osteotomy cut creates a wedge that can be fine-
323 tuned in terms of gap and thereby correction angle. The initial performance results in this
324 proof of concept study indicate that the device facilitates early bone regeneration and
325 shows promise in terms of surgical accuracy and patient satisfaction that can be achieved.
326 More definitive trials are indicated to evaluate the (long-term) performance of OPTY-LINE.

327 **Ethical approval**

328 Approval was obtained from the UK's National Research Ethics Service, North-West Lancaster
329 Committee, reference 16/NW/0017.

330 **Informed consent**

331 Written informed consent was obtained from all participants in accordance with the Declaration of
332 Helsinki (Good Clinical Practice), as part of the study protocol.

333 **References**

- 334 1. Brinkman JM, Luites JW, Wymenga AB, van Heerwaarden RJ. Early full weight bearing is
335 safe in open-wedge high tibial osteotomy: RSA analysis of postoperative stability
336 compared to delayed weight bearing. *Acta orthop* 2010;81:193-198.
- 337 2. Miniaci A, Ballmer FT, Ballmer PM, Jakob RP. Proximal Tibial Osteotomy: A New Fixation
338 Device. *Clin orthop relat res* 1989;246:250-259.
- 339 3. Lansdaal JR, Mouton T, Wascher DC, Demey G, Lustig S, Neyret P, Servien E. Early weight
340 bearing versus delayed weight bearing in medial opening wedge high tibial osteotomy: a
341 randomized controlled trial. *Knee Surgery, Sports Traumatology, Arthroscopy*.
342 2017;25:3670-8.
- 343 4. Kanamiya T, Naito M, Hara M, Yoshimura I. The influences of biomechanical factors on
344 cartilage regeneration after high tibial osteotomy for knees with medial compartment
345 osteoarthritis: clinical and arthroscopic observations. *Arthroscopy: The Journal of*
346 *Arthroscopic & Related Surgery*. 2002 Sep 30;18(7):725-9
- 347 5. Koshino T, Wada S, Ara Y, Saito T. Regeneration of degenerated articular cartilage after
348 high tibial valgus osteotomy for medial compartmental osteoarthritis of the
349 knee. *Knee* 2003;10:229-236
- 350 6. Salzmann GM, Ahrens P, Naal FD, El-Azab H, Spang JT, Imhoff AB, Lorenz S. Sporting
351 activity after high tibial osteotomy for the treatment of medial compartment knee
352 osteoarthritis. *The American journal of sports medicine*. 2009 Feb;37(2):312-8.
- 353 7. Kamada S, Shiota E, Saeki K, Kiyama T, Maeyama A, Yamamoto T. Sports and Physical
354 Activities of Elderly Patients with Medial Compartment Knee Osteoarthritis after High
355 Tibial Osteotomy. *Progress in Rehabilitation Medicine*. 2017;2:20170006.
356 <https://doi.org/10.2490/prm.20170006>
- 357 8. Luites JWH, Brinkman JM, Van Heerwaarden R, Wymenga AB (2009). Fixation stability of
358 opening–versus closing-wedge high tibial osteotomy: a randomised clinical trial using
359 radiostereometry. *J Bone Joint Surg (Br)* 2009;91:1459–65

- 360 9. Takeuchi R, Ishikawa H, Aratake M, Bito H, Saito I, Kumagai K, Akamatsu Y, Saito T. Medial
361 opening wedge high tibial osteotomy with early full weight
362 bearing. *Arthroscopy*. 2009;25:46–53.
- 363 10. Bonnin MP, Laurent JR, Zadegan F, Badet R, Archbold HP, Servien E. Can patients really
364 participate in sport after high tibial osteotomy?. *Knee surgery, sports traumatology,*
365 *arthroscopy*. 2013 Jan 1;21(1):64-73.
- 366 11. Harris WR, Kostuik JP. High tibial osteotomy for osteo-arthritis of the knee. *JBJS*. 1970
367 Mar 1;52(2):330-6.
- 368 12. Nieves JW, Formica C, Ruffing J, Zion M, Garrett P, Lindsay R, Cosman F. Males have larger
369 skeletal size and bone mass than females, despite comparable body size. *J Bone Miner*
370 *Res* 2005;20:529-35
- 371 13. Elson DW, Petheram TG, Dawson MJ. High reliability in digital planning of medial opening
372 wedge high tibial osteotomy, using Miniaci’s method. *Knee Surg Sports Traumatol*
373 *Arthrosc* 2015;23:2041-2048.
- 374 14. Lobenhoffer P, van Heerwaarden RJ, Staubli, AE. Osteotomies around the Knee-
375 Indications-Planning-Surgical Techniques using Plate Fixators. Thieme publishers, 2009.
- 376 15. Schröter S, Ihle C, Elson DW, Döbele S, Stöckle U, Ateschrang A. Surgical accuracy in high
377 tibial osteotomy: coronal equivalence of computer navigation and gap measurement.
378 *Knee Surgery, Sports Traumatology, Arthroscopy*. 2016 Nov 1;24(11):3410-7.
- 379 16. Elson DW. The surgical accuracy of knee osteotomy. *The Knee*. 2017 Mar 1;24(2):167-9.
- 380 17. Bourne RB, Chesworth BM, Davis AM, Mahomed NN, Charron KD. Patient satisfaction
381 after total knee arthroplasty: who is satisfied and who is not? *Clin Orthop Relat*
382 *Res* 2010;468:57-63.
- 383 18. Jorn LP, Johnsson R, Toksvig-Larsen S. Patient satisfaction, function and return to work
384 after knee arthroplasty. *Acta Orthop Scand* 1999;70:343–347
- 385 19. Mahomed N, Gandhi R, Daltroy L, Katz JN. The self-administered patient satisfaction scale
386 for primary hip and knee arthroplasty. *Arthritis*
387 2011; <http://dx.doi.org/10.1155/2011/591253>
- 388

- 389
- 390 20. Brosset T, Pasquier G, Migaud H, Gougeon F. Opening wedge high tibial osteotomy
391 performed without filling the defect but with locking plate fixation (TomoFix™) and early
392 weight-bearing: prospective evaluation of bone union, precision and maintenance of
393 correction in 51 cases. *Orthop Traumatol Surg Res* 2011;97:705-711
- 394 21. Müller ME, Allgöwer M, Perren SM. Manual of internal fixation: techniques
395 recommended by the AO-ASIF group. Springer Science & Business Media, 199
- 396 22. Roos EM, Lohmander LS. The Knee injury and Osteoarthritis Outcome Score (KOOS): from
397 joint injury to osteoarthritis. *Health qual life outcomes*,2003;1:64.
- 398 23. Paley D. PRECICE intramedullary limb lengthening system. *Expert rev med*
399 *devices*, 2015;12:231-49.
- 400 24. Kirane YM, Fragomen AT, Rozbruch SR. Precision of the PRECICE® internal bone
401 lengthening nail. *Clin Orthop Relat Res* 2014;472:3869-78
- 402 25. Schiedel FM, Vogt B, Tretow HL, Schuhknecht B, Gosheger G, Horter MJ, Rödl R. How
403 precise is the PRECICE compared to the ISKD in intramedullary limb lengthening?
404 Reliability and safety in 26 procedures. *Acta orthop* 2014;85:293-8
- 405 26. Staubli AE, De Simon C, Babst R, Lobenhoffer P. TomoFix: a new LCP-concept for open
406 wedge osteotomy of the medial proximal tibia: early results in 92 cases. *Injury*
407 2003;34(Suppl 2):55-62
- 408 27. Lobenhoffer P, Agneskirchner J, Zoch W. Open valgus alignment osteotomy of the
409 proximal tibia with fixation by medial plate fixator. *Orthopade* 2004;33:153-60 (in
410 German).
- 411 28. Staubli AE, De SC, Babst R, Lobenhoffer P. TomoFix: a new LCP-concept for open wedge
412 osteotomy of the medial proximal tibia--early results in 92 cases. *Injury* 2003;34:B55-
413 B62.
- 414 29. Markel MD, Wikenheiser MA, Morin RL, Lewallen DG, Chao EY. Quantification of bone
415 healing: comparison of QCT, SPA, MRI, and DEXA in dog osteotomies. *Acta Orthop*
416 *Scand* 1990;61:487-498.
- 417

- 418 30. Brinkman JM, Lobenhoffer P, Agneskirchner JD, Staubli AE, Wymenga AB, Van
419 Heerwaarden RJ. Osteotomies around the knee. *Bone & Joint Journal*. 2008 Dec
420 1;90(12):1548-57.
- 421 31. Staubli AE. Radiologische heilungsvorgange nach offnender kniegelenknahe
422 Tibiaosteotomie. In: Lobenhoffer P, Agneskirchner JD, Galla M, eds, *Kniesgelenknahe*
423 *osteotomien: indikation, planung, operations technik mit platten fixateuren*. Stuttgart:
424 Georg Thieme Verlag, 2006:65-78
- 425 32. Augat P, Margevicius K, Simon J, Wolf S, Suger G, Claes L (1998). Local tissue properties in
426 bone healing: influence of size and stability of the osteotomy gap. *J Orthop*
427 *Res* 1998;16:475-481.
- 428 33. Claes L, Augat P, Suger G, Wilke HJ. Influence of size and stability of the osteotomy gap on
429 the success of fracture healing. *J Orthop Res* 1997;15:577-584.
- 430 34. Perren SM. Evolution of the internal fixation of long bone fractures. *Bone & Joint*
431 *J* 2002;84:1093-1110.
- 432 35. Schröter S, Freude T, Kopp MM, Konstantinidis L, Döbele S, Stöckle U, van Heerwaarden,
433 R. Smoking and unstable hinge fractures cause delayed gap filling irrespective of early
434 weight bearing after open wedge osteotomy. *Arthroscopy*, 2015;31: 254-265.
435
436
437
438
439
440
441
442
443

444

445 **Table 1, demographics and baseline characteristics of study subjects**

Parameter	OPTY-LINE (n = 6)	Tomofix (n = 5)	p-value
Age, mean in yrs (mean SD) [#]	51 (8)	49 (11)	0.79
Weight, mean in kg (mean SD) [#]	88 (18)	97 (18)	0.43
Height, mean in cm (mean SD) [#]	178 (5)	179 (7)	0.54
BMI, mean in kg/m ² (mean SD) [#]	28 (6)	30 (5)	0.54
Leg affected, n (left/right) [@]	4 / 2	5 / 0	0.46
Length of stay, mean in days (range) [#]	1 (1)	1 (1-2)	0.66

446 # Mann-Whitney U-test, two-sided; @ Fisher's exact test

447 **Table 2, Radiologists' impression scores and quantitative assessment of bone healing**

Time point	Type of rating	OPTY-LINE (median; min to max)	Tomofix (median; min to max)	p-value [#]
3 months post-operatively	A			
	Average of 2 raters	1.75 (1 to 2)	0.5 (0 to 2)	0.041 [^]
	Inter-rater concordance*	0.83	0.80	
	B			
	Average of 2 raters	0.40 [0.19]	0.32 [0.077]	0.27
6 months post-operatively	A			
	Average of 2 raters	4 (3 to 4)	2 (1 to 4)	0.041 [^]
	Inter-rater concordance*	1	1	
	B			
	Average of 2 raters	1.78 [1.58]	1.30 [1.74]	0.089
	Inter-rater concordance*	0.89	0.64	
Scoring values	<p>A: Radiologist's impression score 0 = no healing (0-20%); 1 = some healing (21-40%); 2 = progressive healing (41-60%); 3 = advanced healing (61-80%); 4 = union virtually complete (81-100%)</p> <p>B: Digital quantification of bone healing Bone density quotient = ROI defect area / ((ROI superior area + ROI inferior</p>			

	area)/2)
--	----------

448 * Measured with Kendall's coefficient of concordance (W); # - One-sided Mann-Whitney U-test;

449 ^p-value < 0.05 considered statistically significant; ROI = region of interest.

450

451 **Table 3, Analysis of achieved versus intended Mikulicz at 3 & 6 months follow-up.**

Device	Patient no.	Planned Mikulicz value	Achieved Mikulicz value, 3 months [SD]	Surgical accuracy targeting error*	Surgical accuracy (absolute value, [SD])	Achieved Mikulicz value, 6 months [SD]	Surgical accuracy targeting error*	Surgical accuracy (absolute value, [SD])
OPTY-LINE	1	55	50	-5	5	48	-7	7
	2	55	58.9	3.9	3.9	53	-2	2
	3	55	53.4	-1.6	1.6	51	-4	4
	4	55	54.9	-0.1	0.1	51.8	-3.2	3.2
	5	55	55.6	0.6	0.6	53.3	-1.7	1.7
	6	55	60.3	5.3	5.3	61.6	6.6	6.6
	Mean				2.8 [2.3]			4.1 [2.3]
Tomofix	7	50	67.4	17.4	17.4	73	23	23
	8	55	66	11	11	71.2	16.2	16.2
	9	55	64	9	9	63.8	8.8	8.8
	10	55	49.2	-5.8	5.8	48.8	-6.2	6.2
	11	55	53.7	-1.3	1.3	49.4	-5.6	5.6
	Mean				8.9 [6.0]			12 [7.5]
p-value# (OPTY-LINE vs Tomofix)					0.052			0.052

452 * A value of 0 equates to accuracy of 100% (achieved Mikulicz – intended Mikulicz [Elson, 2017]).

453 #Mann-Whitney U-test, two-sided; p-value < 0.05 considered statistically significant.

454

455

456

457

458

459

460

461

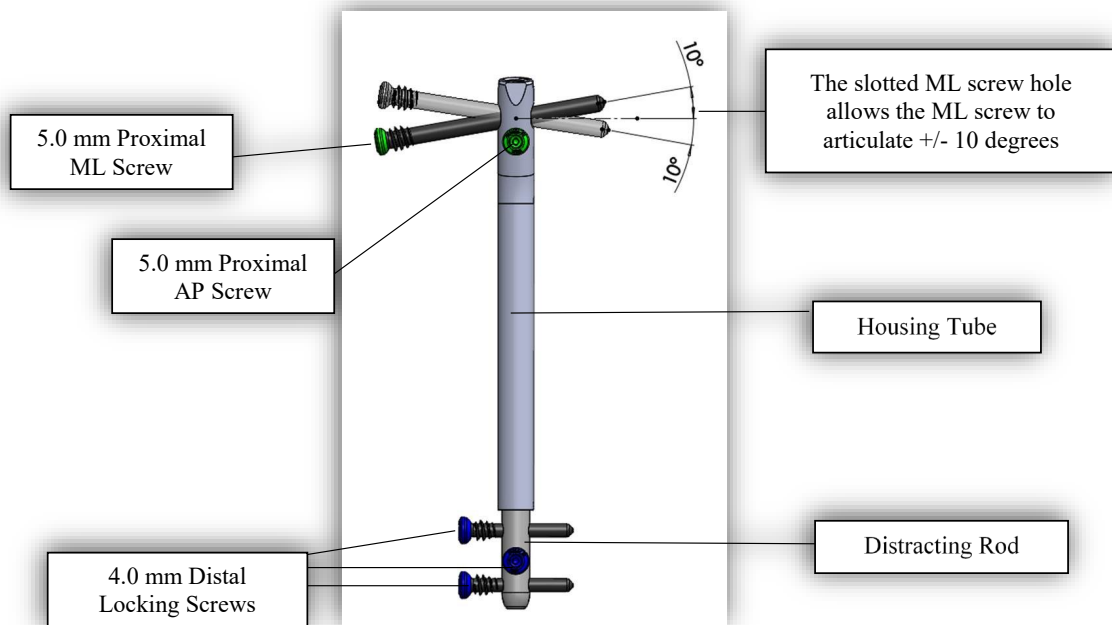
462

463 **Figure 1, OPTY-LINE device for high tibial osteotomy**

464 A - Schematic drawing of the complete device, depicting the locations of the four screws for fixation and
465 the housing tube containing magnet, gears and threaded pin which is distracted in stages post-
466 operatively. ML = medial-lateral; AP = antero-posterior. Image courtesy of Nuvasive Specialized
467 Orthopedics.

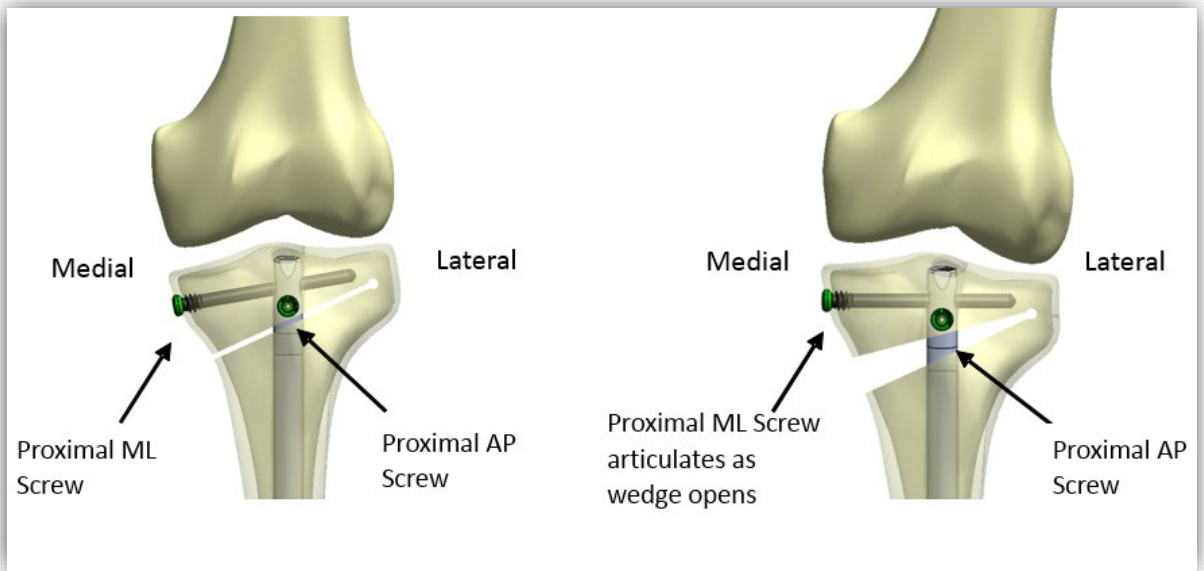
468 B - Schematic drawings of the status of the high tibia and knee joint immediately post-surgery (left) and 6
469 weeks later (right) following distraction of the rod within the OPTY-LINE device. Image courtesy of
470 Nuvasive Specialized Orthopedics.

471 **A**



472

473 **B**



474

475

476

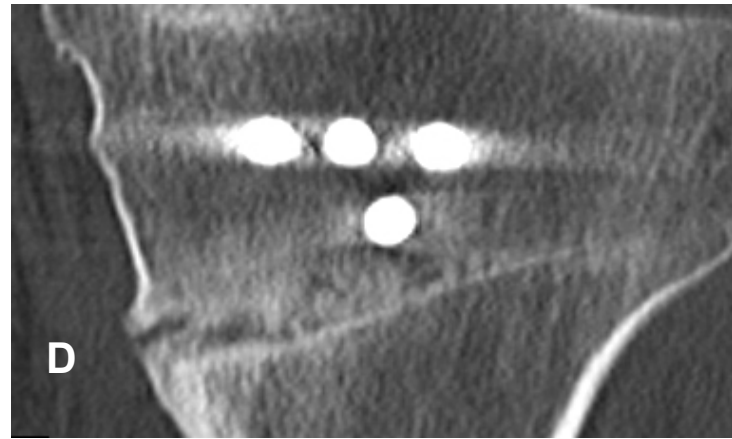
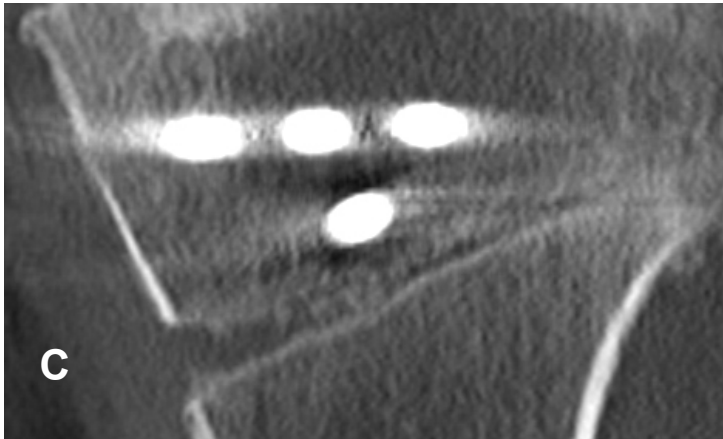
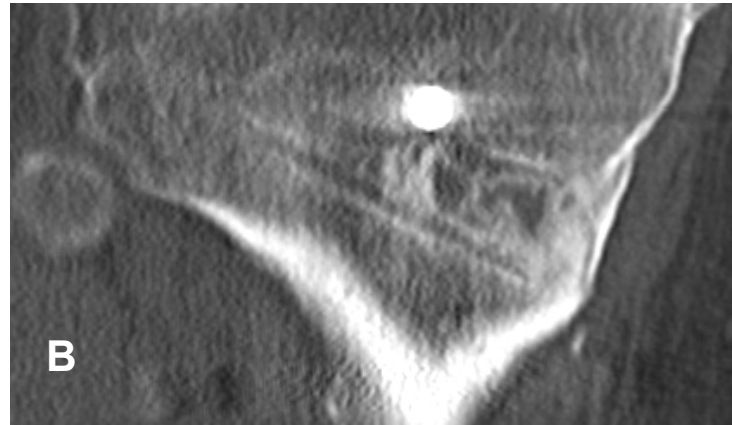
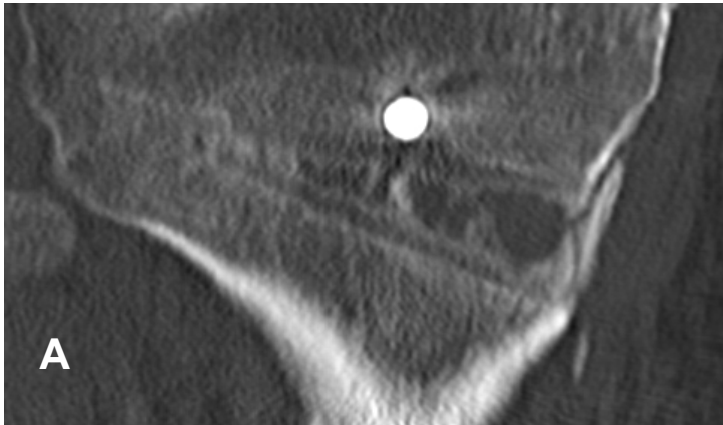
477

478 **Figure 2, Representative coronal imaging of osteotomy lesions at 3 & 6 months post-surgery**

479 With both the Tomofix and OPTY-LINE device there an increase in callus formation is observed when the
480 two post-surgical timepoints of 3 and 6 months are compared (A vs B and C vs D) respectively. At 3 and 6
481 months the healing for Tomofix cases compared to OPTY-LINE is less pronounced at particularly the
482 medial edge of the osteotomy gap (A vs C and B vs D respectively). A, OPTY-LINE at 3 months; B, OPTY-
483 LINE at 6 months; C, Tomofix at 3 months; D, Tomofix at 6 months.

484

485



486

487

488

489

490

491

